


Retina Conference



Maya Bitar, M.D.

University of Louisville

Department of Ophthalmology and Visual Sciences

9/09/10

Presentation

CC: “Spot in central vision”

HPI: 40 year WF c/o sudden onset of spot in central vision of R eye since she woke up 3 weeks ago. Her symptoms vary from a black spot to central blurriness.

POH: Duane’s Syndrome (Sd), myopia

PMH: Allergic rhinitis

Meds: Cetirizine

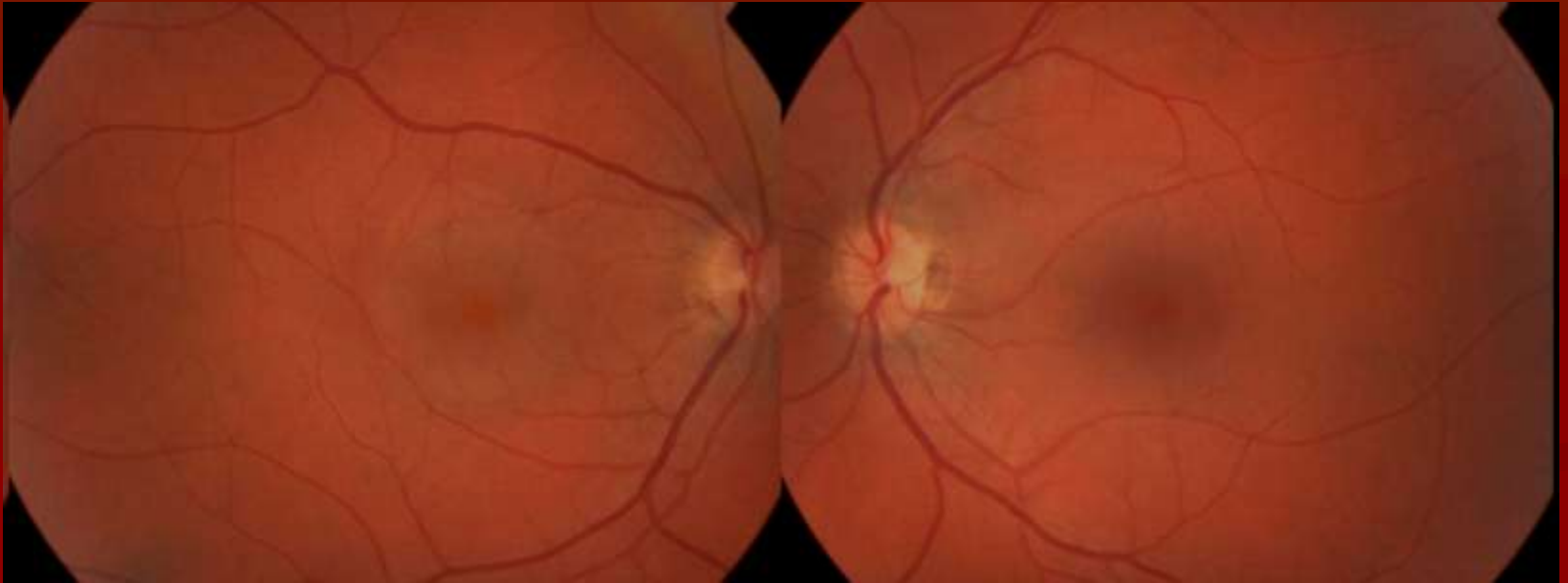
Allergies: NKDA

Social Hx: School manager, smoker, adopted as a child

Physical Examination

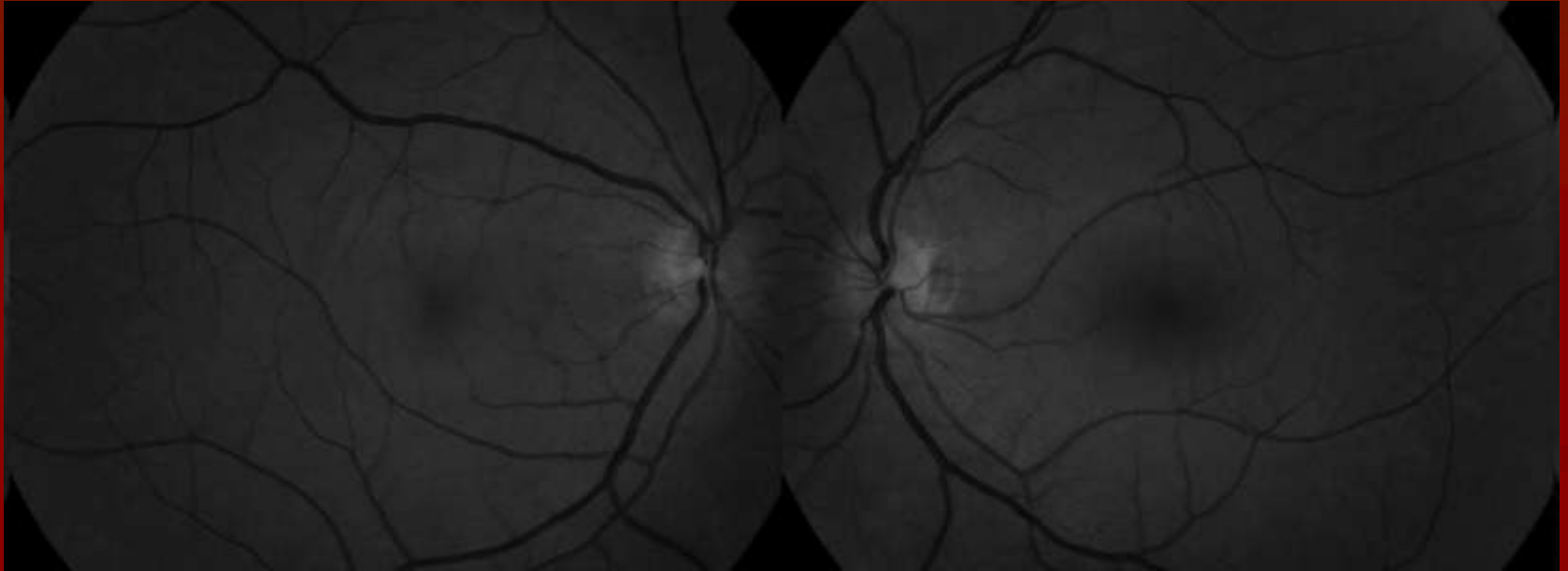
	OD	OS
<u>BCVA:</u>	20/30 ⁻¹	20/20
<u>IOP:</u>	13	12
<u>Pupils:</u>	4 → 2mm OU no RAPD	
<u>EOM:</u>	Restricted R gaze	
<u>VF:</u>	Paracentral scotoma	WNL
<u>SLE:</u>	WNL	WNL

Color Fundus Photo



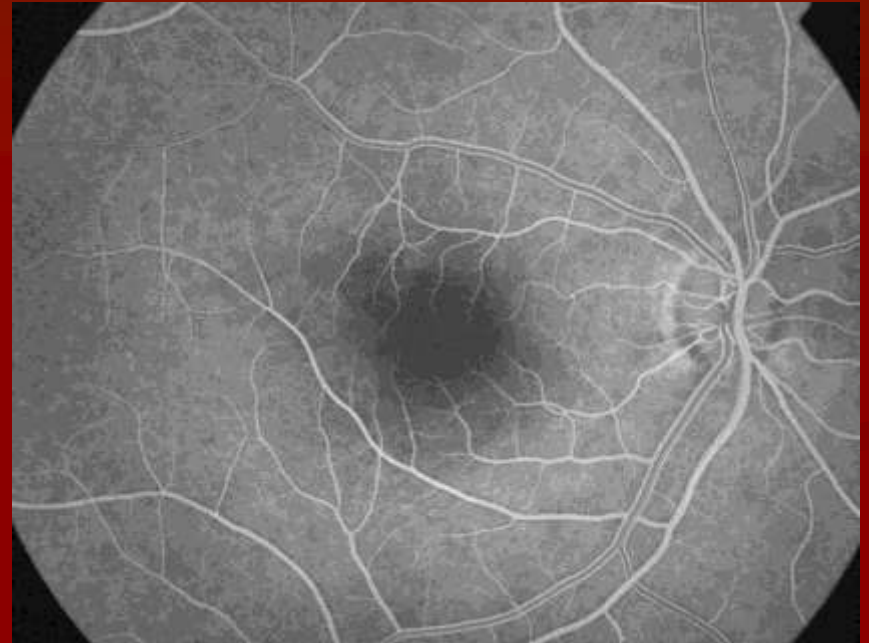
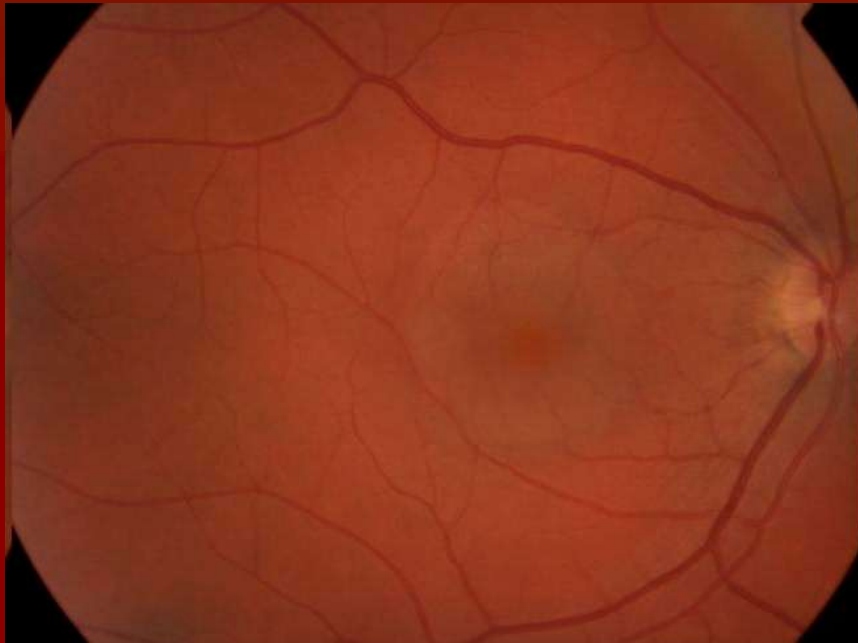
Color fundus photograph showing a well circumscribed serous elevation of the macula OD. OS: WNL

Red free photos



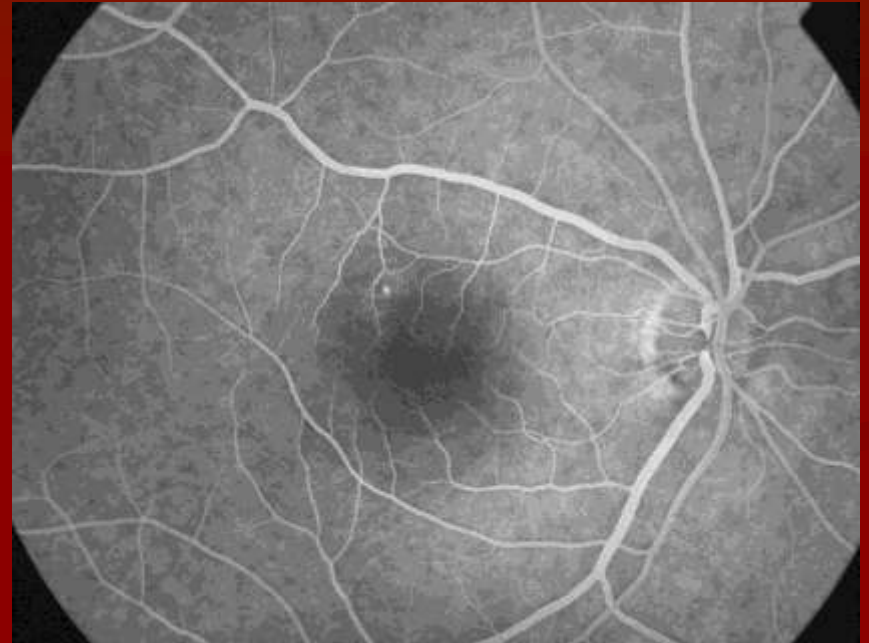
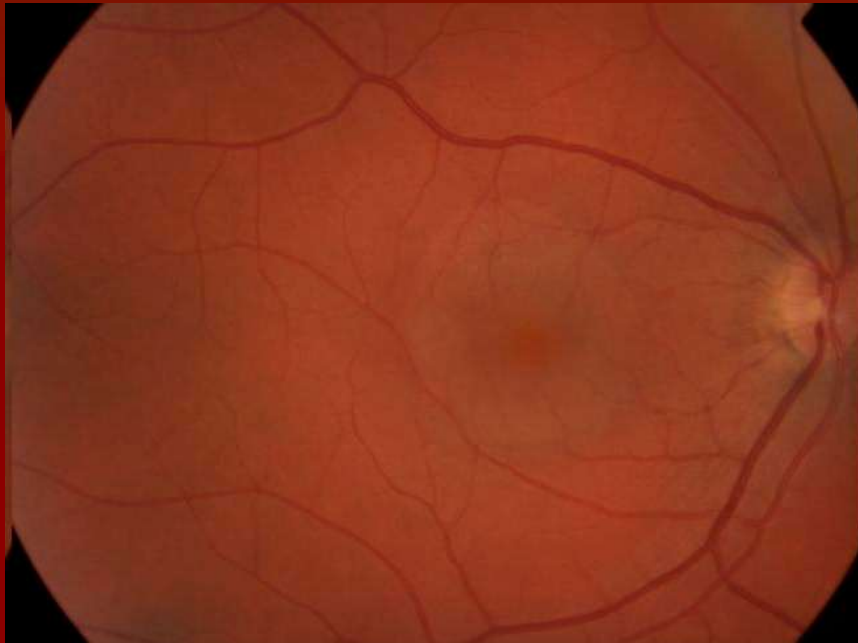
Red free photo showing again subretinal fluid in the macula
OD, OS: WNL

Fluorescein Angiography



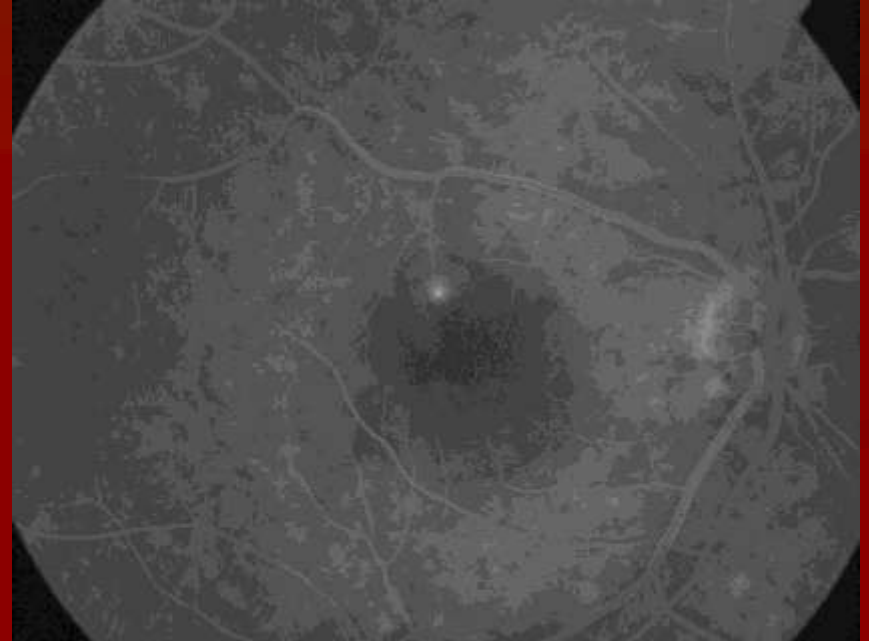
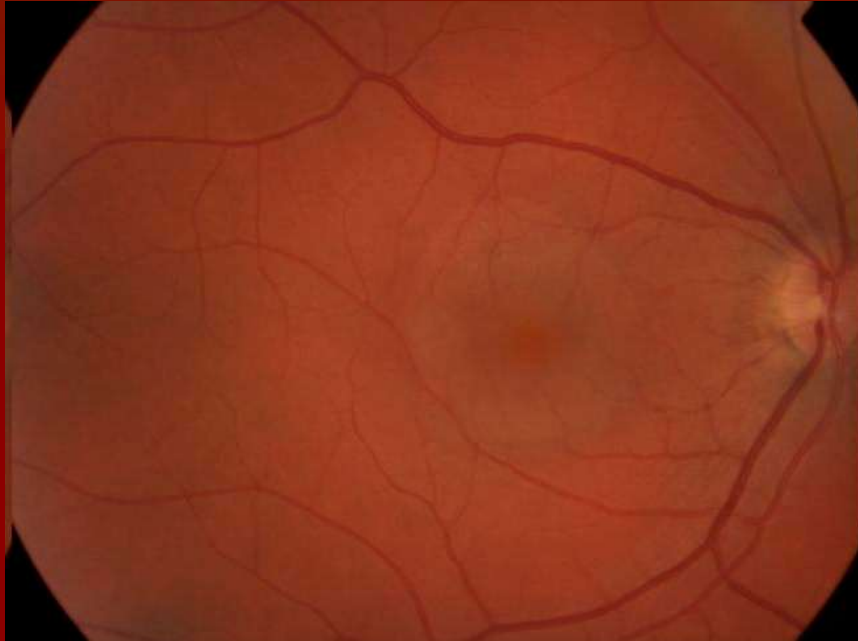
Early AV phase – OD showing a small dot of hyperfluorescence supero-temporal to the fovea.

Fluorescein Angiography



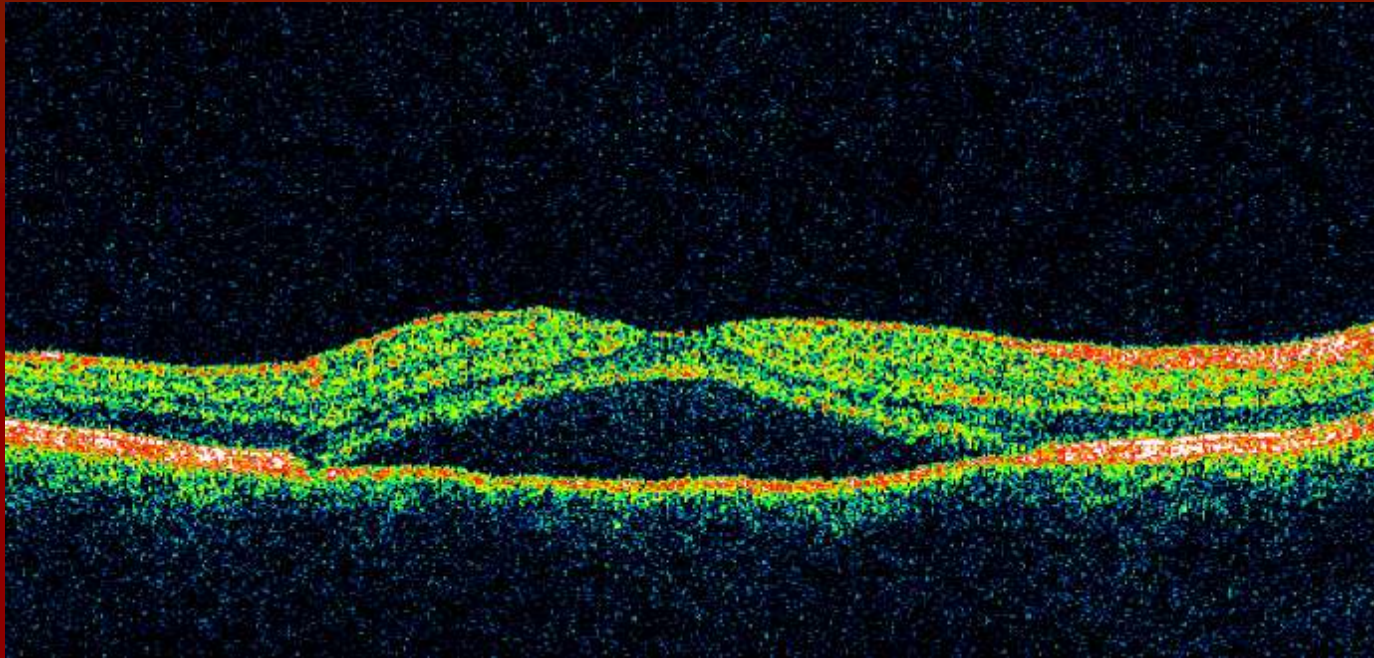
Mid AV phase – OD showing increase in size and intensity of hyperfluorescent dot

Fluorescein Angiography



Recirculation phase – OD showing expanding hyperfluorescent dot supero-temporal to the fovea

OCT



OCT OD showing serous neurosensory detachment in the macula

Impression

Central Serous Chorioretinopathy (CSCR)

Differential Diagnosis

- Idiopathic choroidal polypoidal vasculopathy
- Pigment epithelial detachment
- Choroidal tumors
- Inflammatory choroiditis - Idiopathic uveal effusion Sd

Patient's Evolution

- Plan: observation for 3 months
- 3 month follow-up (f/u):
 - “vision in R eye is improved but still not as clear as L eye”
 - BCVA: 20/30 OD
 - OCT OD: resolution of neurosensory detachment
- 9 month f/u:
 - BCVA: 20/20 OD

Central Serous Chorioretinopathy

■ Epidemiology:

- Men (80%) >> Women
- Age range: 25-50 yo
- In women: . occurs at older age
 - . associated with pregnancy
- Rare in african americans
- Unilateral (60%)

Pathophysiology

- Well circumscribed serous detachment of sensory retina with RPE changes +/- RPE detachment
- Mechanisms:
 - Altered RPE barrier and pumping functions
 - Choroidal microcirculation abnormalities:
 - . localized vasoconstriction, hypermeability
 - . impaired fibrinolysis
 - occlusion of choriocapillaries with decreased foveal choroidal blood flow

Associated Factors

- Glucocorticoid: . exogenous (inhaled, systemic, local injections) (prevalence of association 10-52%)^{1,2}
. endogenous hypercortisolism

Link: endogenous serum cortisol more than 50% elevated in patient with CSCR³

- Psychosocial stress: ↑emotional distress compared with other eye diseases and ↑ type A behavior - accepts great burdens while obtaining little relief of tension⁴

Link: ↑ circulating catecholamines that return to normal during convalescent stage of CSCR⁵ and ↑cortisol

- Helicobacter pylori:

significantly higher prevalence of H pylori infection in CSCR patients compared to age matched population⁶

Link: possible immune mechanism, based on a "molecular mimicry" between pathogenic antigens expressed on the bacterium and homologous host proteins

- Other: uncontrolled hypertension

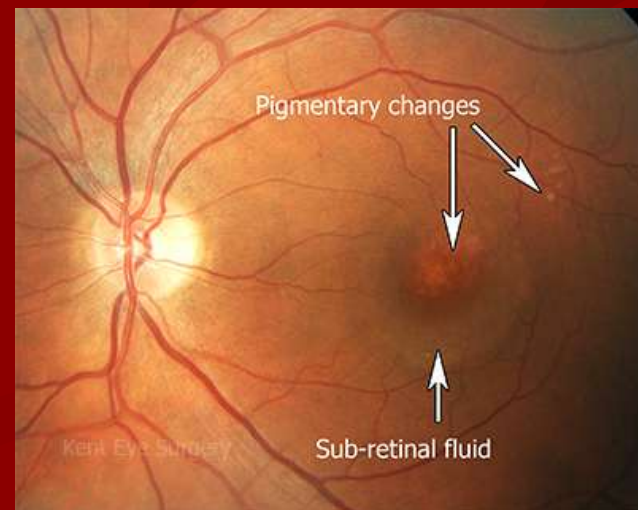
Symptoms and Signs

- Sudden onset of blurred and dim vision, micropsia, metamorphopsia, paracentral scotoma, decreased color vision, migraine-like headache (rarely)
- VA usually 20/30, hyperopic shift, Amsler grid showing distortion of lines with scotoma

CSCR Diagnosis

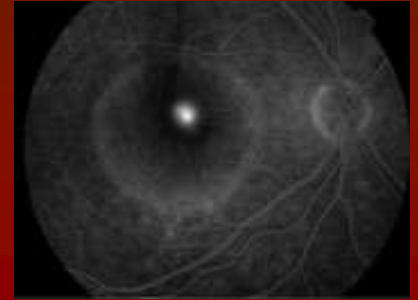
- DFE: localized serous detachment in the macula without blood or lipid exudates.

Sometimes: Serous RPE detachment. Whitish subretinal fibrin deposits and focal RPE irregularities in chronic CSCR and as sequellae of previous episodes

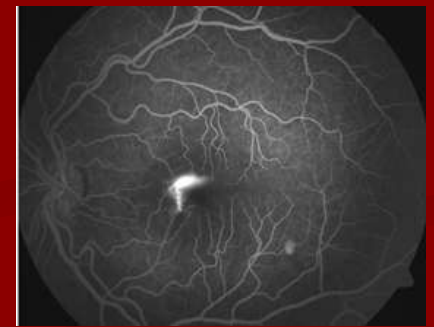
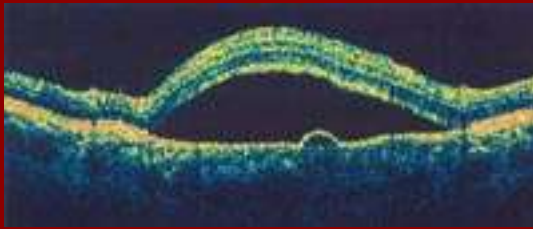
Imaging modalities

- FA: expansile dot of hyperfluorescence - leak from choroid through RPE, pooling of dye into subretinal detachment, “smokestack “ pattern



- OCT:



- ICG: choroidal vascular abnormalities, mostly useful in atypical cases.

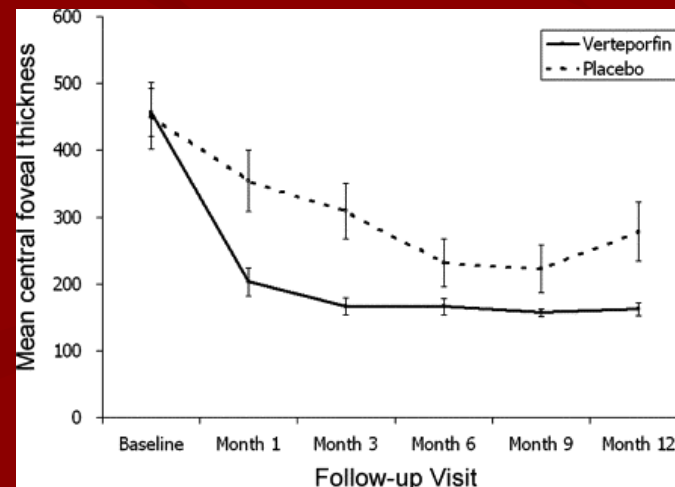
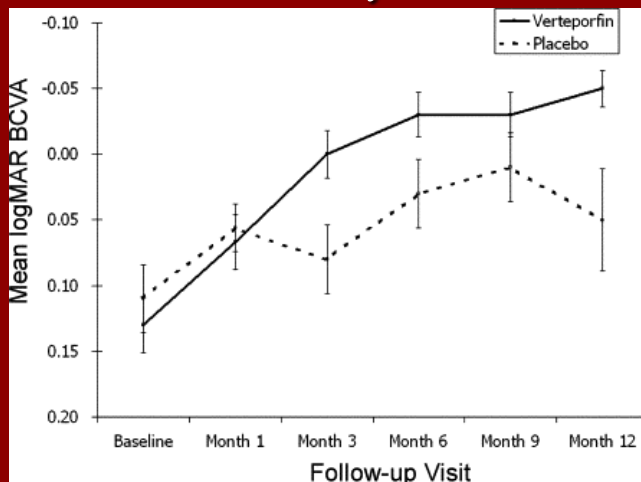
Course

- Duration of symptoms/retinal detachment < 6 months (1.5 months in 90% of cases)⁷
- Good long term prognosis
- Risk of CNV
- Recurrence in one third to half of cases → reduced final visual function

- Clinical factors related to visual outcomes:
 - Prospective case series of 46 eyes, mean f/u 22.8 months⁸
 - Statistically significant correlation between baseline BCVA , duration of symptoms and final BCVA
 - Shorter periods of subfoveal fluid correlated with better VA.
 - Both baseline and final BCVA were strongly correlated with foveal thickness after fluid resolution
 - Angiographic pattern were not significantly correlated with better VA.

Management

- Observation for 3 months, counseling about stress and glucocorticoid medications
- Laser photocoagulation: earlier resolution of detachment.
 - for persistent detachment or recurrent disease with visual deficit from previous episodes
- Verteporfin Photodynamic therapy: improve VA & foveal thickness⁹
 - Prospective, double-masked, placebo-controlled, randomized clinical trial studied 63 eyes with acute CSCR ≤ 3 months duration



- Beta-blockers? small uncontrolled case series showed promising result ¹⁰
- Aspirin? more rapid recovery of BCVA and maintenance of better BCVA at 2y f/u compared with historic controls¹¹
- Intravitreal Bevacizumab? No effect in acute CSCR compared to control in a randomized study with 6 months f/u¹²

Thank You!

References

1. Tittl MK, Spaide RF, Wong D, Pilotto E, Yannuzzi LA, Fisher YL, Freund B, Guyer DR, Slakter JS, Sorenson JA. Systemic findings associated with central serous chorioretinopathy. *Am J Ophthalmol*. 1999 Jul;128(1):63-8.
2. Karadimas P, Bouzas EA. Glucocorticoid use represents a risk factor for central serous chorioretinopathy: a prospective, case-control study. *Graefes Arch Clin Exp Ophthalmol*. 2004 Sep;242(9):800-2.
3. Garg SP, Dada T, Talwar D & Biswas NR. Endogenous cortisol profile in patients with central serous chorioretinopathy. *Br J Ophthalmol* .1997 81: 962–964.
4. Conrad R, Weber NF, Lehnert M, Holz FG, Liedtke R, Eter N. Alexithymia and emotional distress in patients with central serous chorioretinopathy. *Psychosomatics*. 2007 Nov-Dec;48(6):489-95.
5. Sun J, Tan J, Wang Z, Yang H, Zhu X & Li L : Effect of catecholamine on central serous chorioretinopathy. *J Huazhong Univ Sci Technolog Med Sci* (2003)23: 313–316.
6. Cotticelli L, Borrelli M, D'Alessio AC et al.: Central serous chorioretinopathy and *Helicobacter pylori*. *Eur J Ophthalmol* 2006. 16: 274–278.
7. Wong R, Chopdar A, Brown M. Five to 15 year follow-up of resolved idiopathic central serous chorioretinopathy. *Eye* 2004;18:262–268.

8. Aggio FB, Roisman L, Melo GB, Lavinsky D, Cardillo JA, Farah ME. Retina. Clinical factors related to visual outcome in central serous chorioretinopathy. 2010 Jul-Aug;30(7):1128-34.
9. Chan WM, Lai TY, Lai RY, Liu DT, Lam DS. Half-dose verteporfin photodynamic therapy for acute central serous chorioretinopathy: one-year results of a randomized controlled trial. Ophthalmology. 2008 Oct;115(10):1756-65. Epub 2008 Jun 5.
10. Avci R & Deutman AF (2005): Die Behandlung der zentralen serösen Choroidopathie mit dem Betarezeptorenblocker Metoprolol (Vorläufige Ergebnisse) . Klin Monatsbl Augenheilkd 202: 199–205.
11. Caccavale A, Romanazzi F, Imperato M, Negri A, Morano A, Ferentini F. Low-dose aspirin as treatment for central serous chorioretinopathy. Clin Ophthalmol. 2010 Aug 9;4:899-903.
12. Lim JW, Ryu SJ, Shin MC. The effect of intravitreal bevacizumab in patients with acute central serous chorioretinopathy. Korean J Ophthalmol. 2010 Jun;24(3):155-8. Epub 2010 Jun 5.