


Retina Conference



Michael R. George, M.D.

University of Louisville

Department of Ophthalmology and Visual Sciences

7/2/10

Subjective

CC/HPI: 22 yo Caucasian female presented with a complaint of decreased vision in her left eye. She describes a sudden onset, stating that “I woke up and my left eye couldn’t see”.

POH: Refractive Error (~ -4.75 D Myopia OU)

PMH: None

MEDS: None

FamHx: Mother with glaucoma

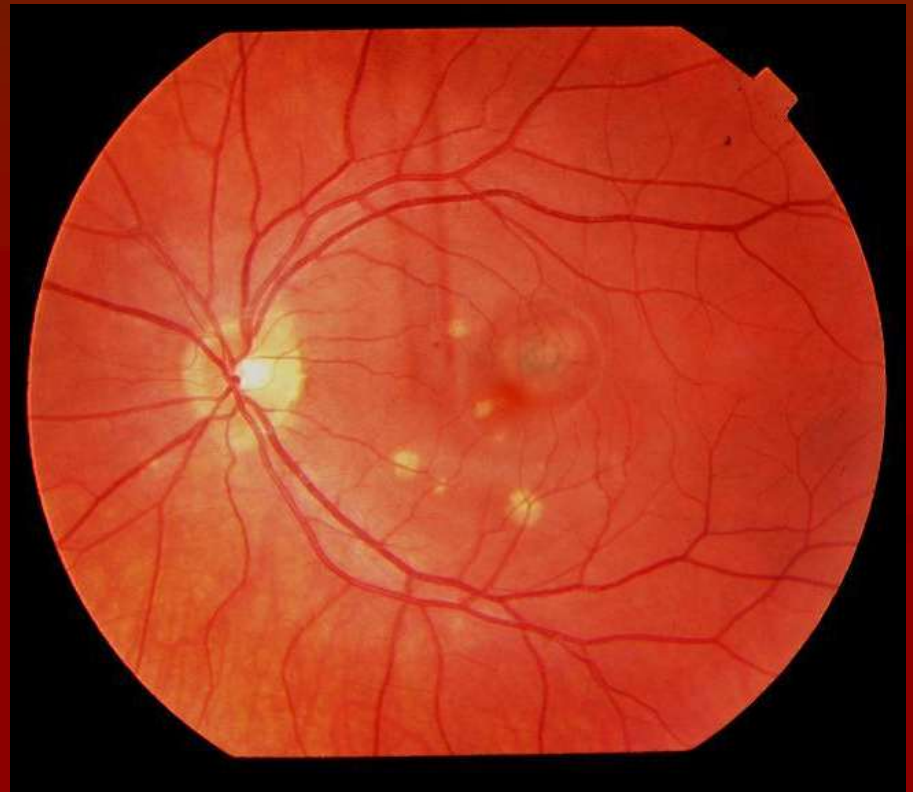
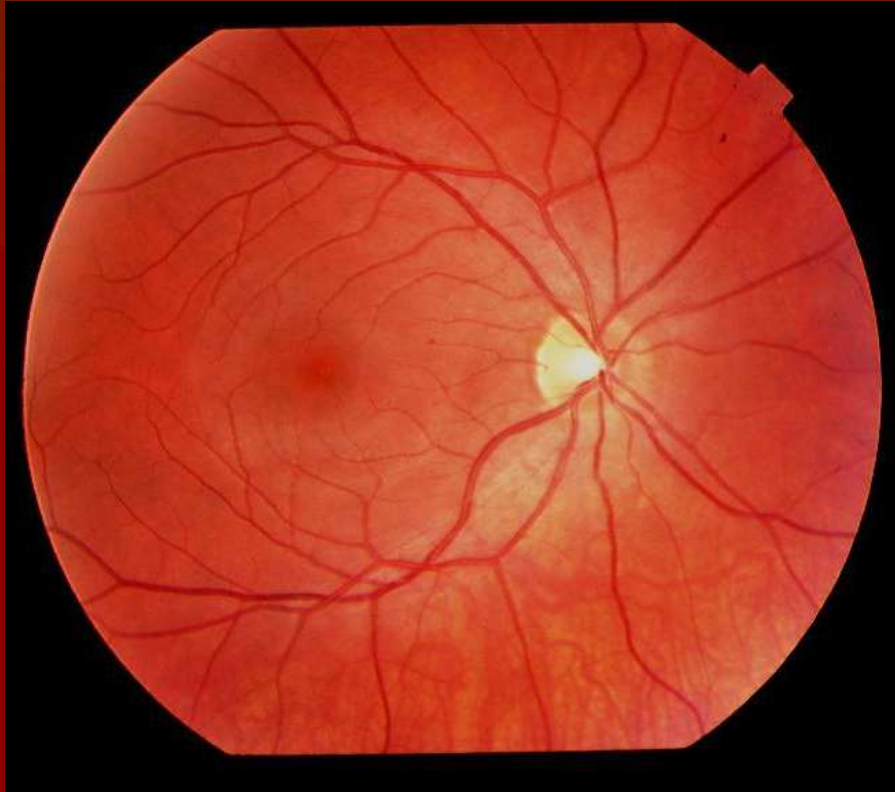
Objective

	OD	OS
<u>BCVA:</u>	20/20	20/60 ⁺¹
<u>IOP:</u>	11	15

Pupils: 5mm Round & Reactive OU

Ant.Seg.: WNL OU

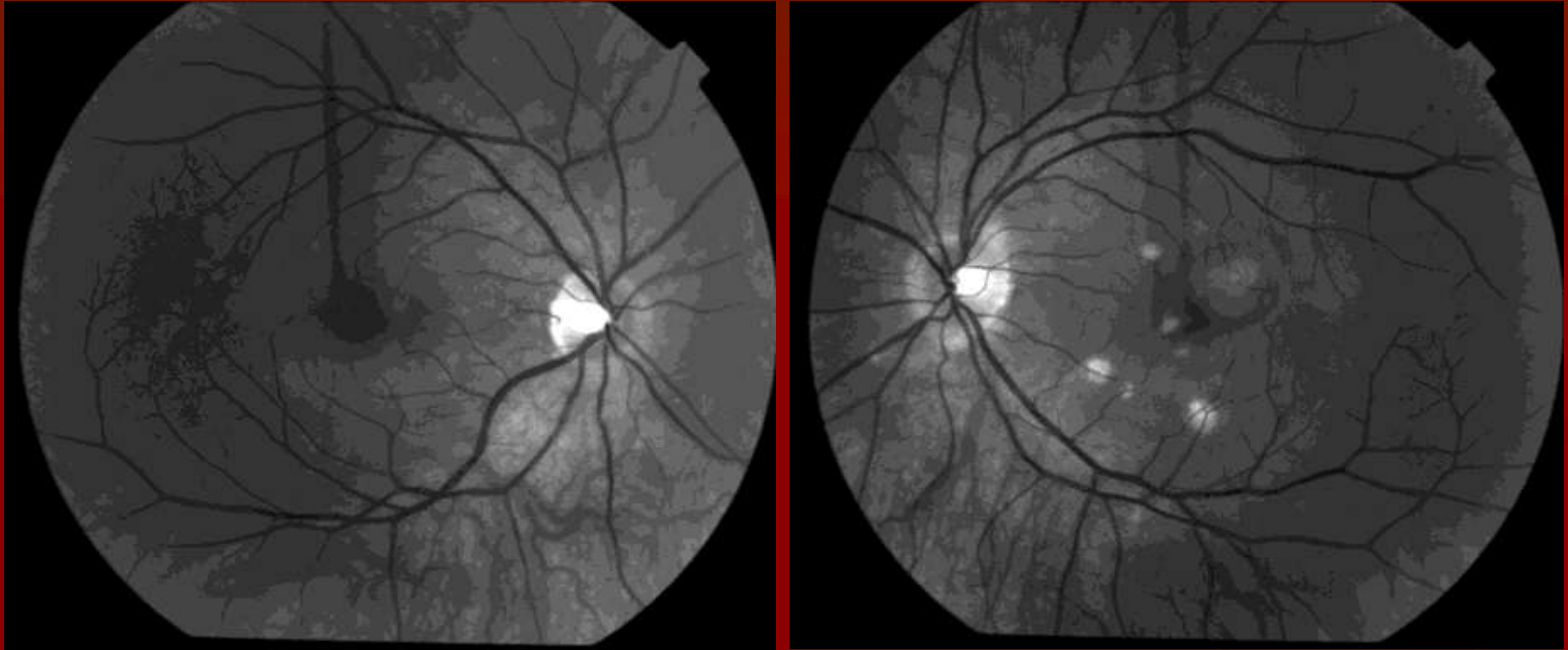
Fundus photos



Color fundus photo of right eye [left] with essentially normal appearance.

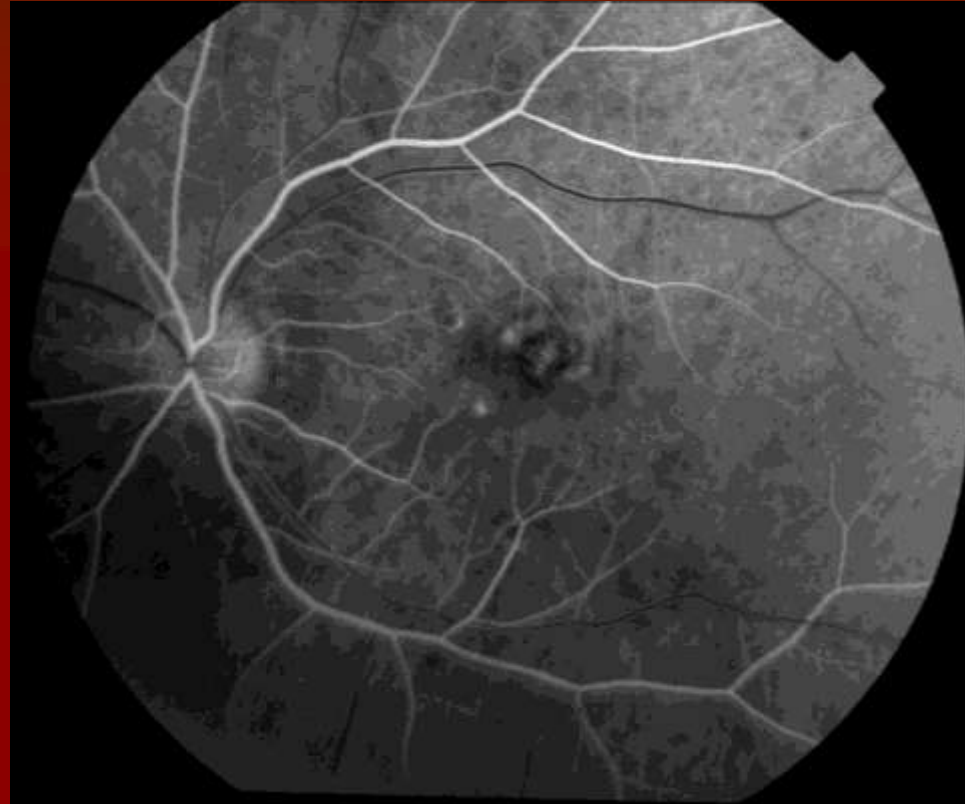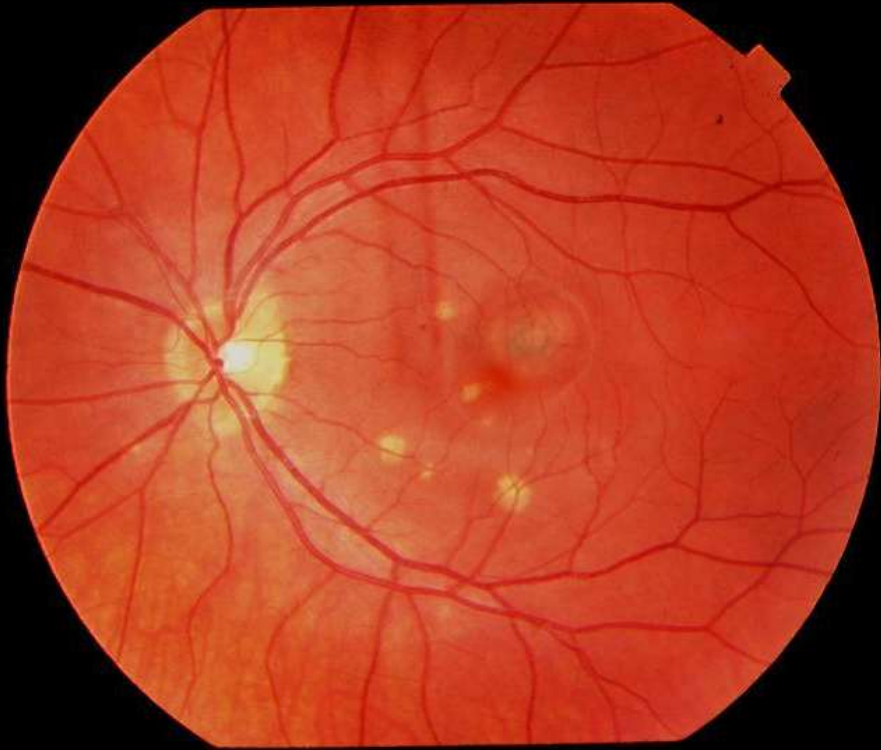
Color fundus photo of left eye [right] with multiple discrete hypopigmented circular lesions in the macula. A larger circular retinal lesion with a hyperpigmented central zone is seen on the temporal side of the fovea, with distortion of the overlying vasculature.

Red Free Photos



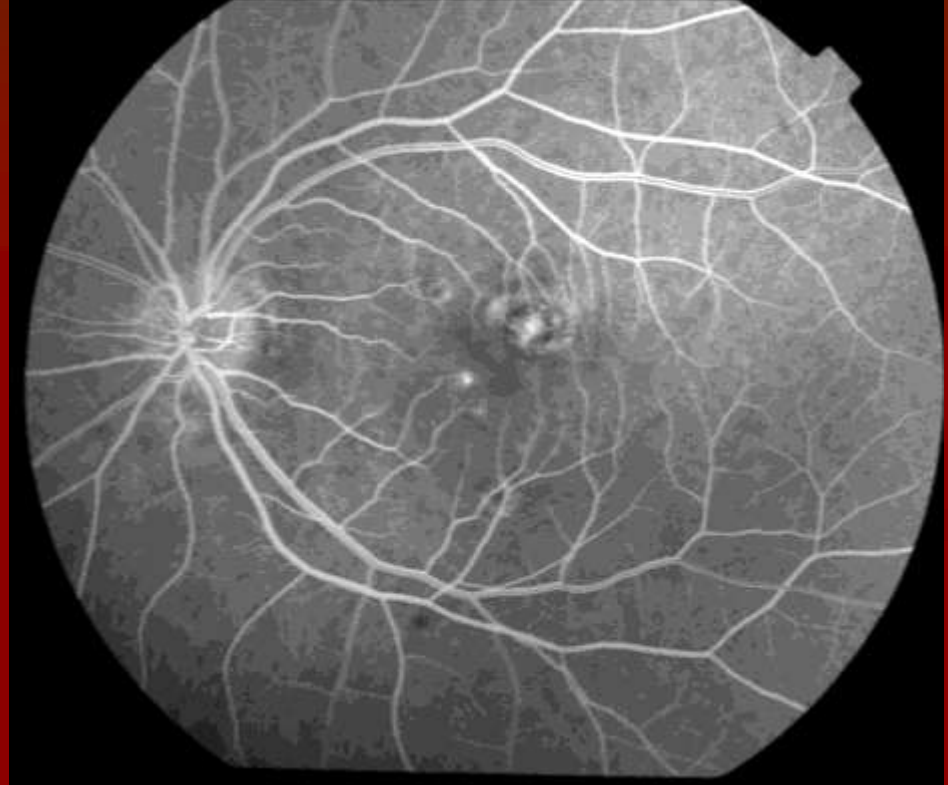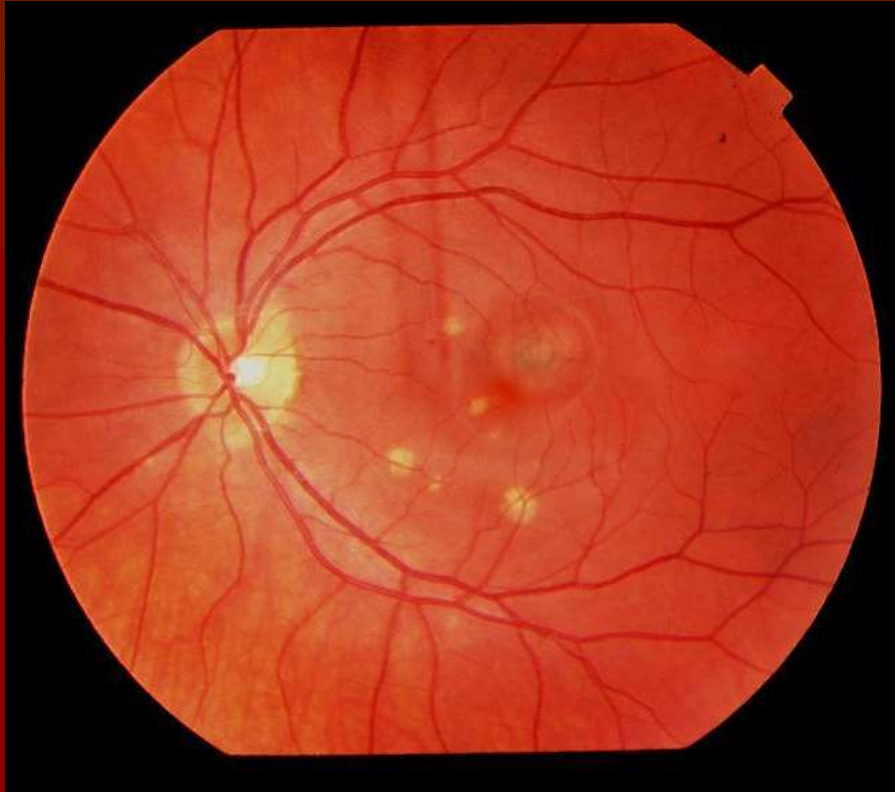
Red free photos of the right fundus [left] and left fundus [right] for comparison. Previously noted lesions in the left eye are visible, with more discernable borders of the larger juxtafoveal lesion.

FA



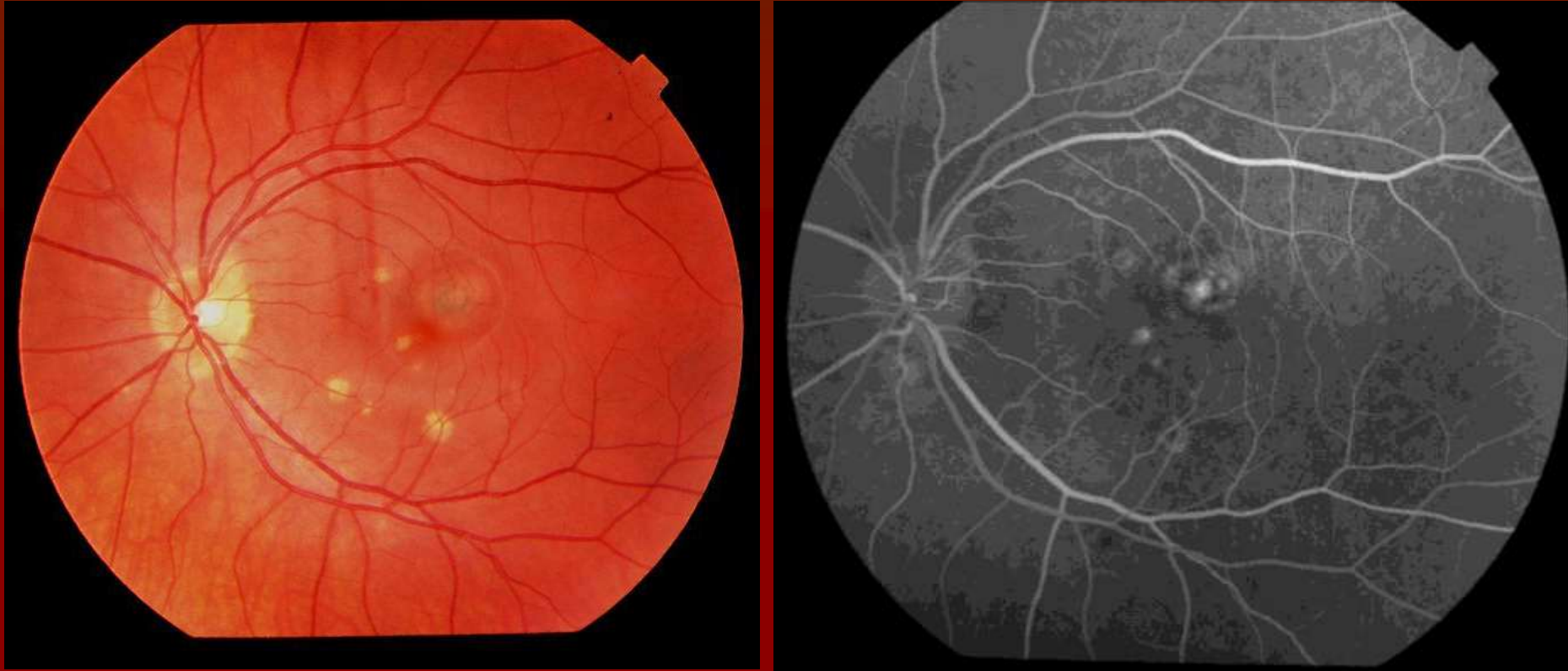
Color Fundus Photo [left] and early-AV phase of fluorescein angiogram [right] of left eye showing mottled hyperfluorescence appearing within the area of the juxtafoveal lesion, as well as corresponding to some of the hypopigmented lesions.

FA



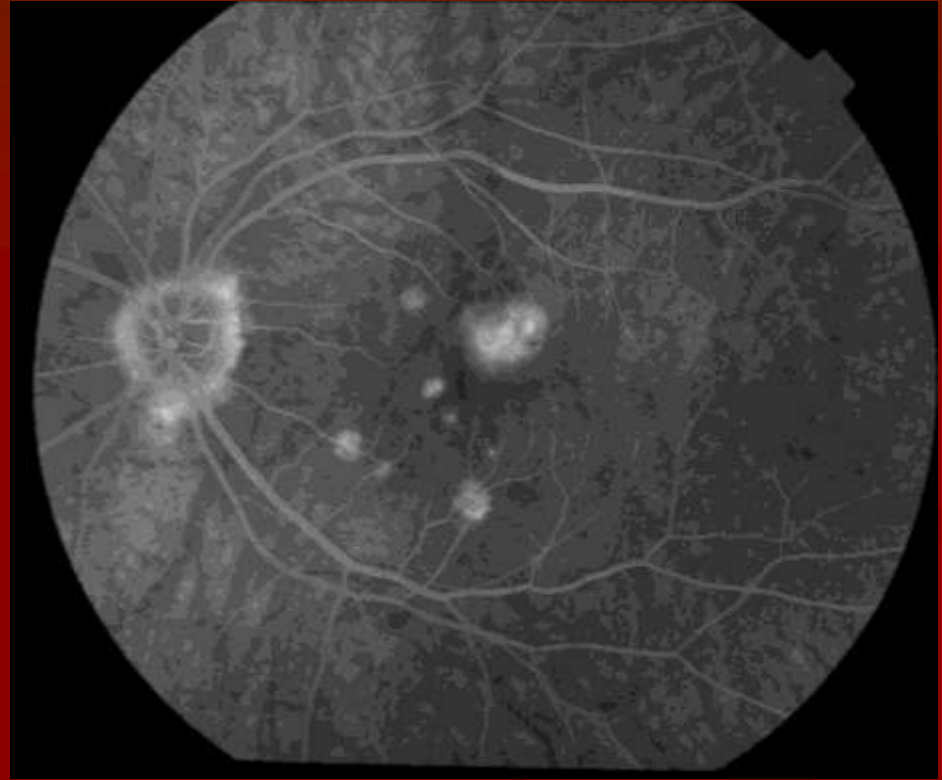
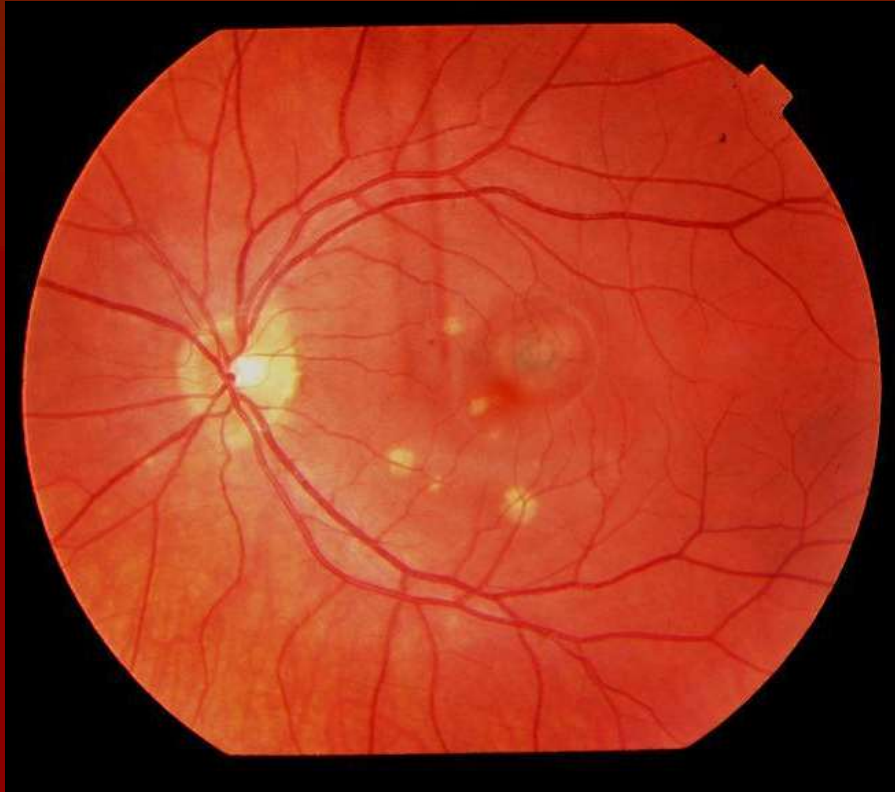
Color Fundus Photo [left] and mid-AV phase of fluorescein angiogram [right] of left eye showing increasing hyperfluorescence within the lesions.

FA



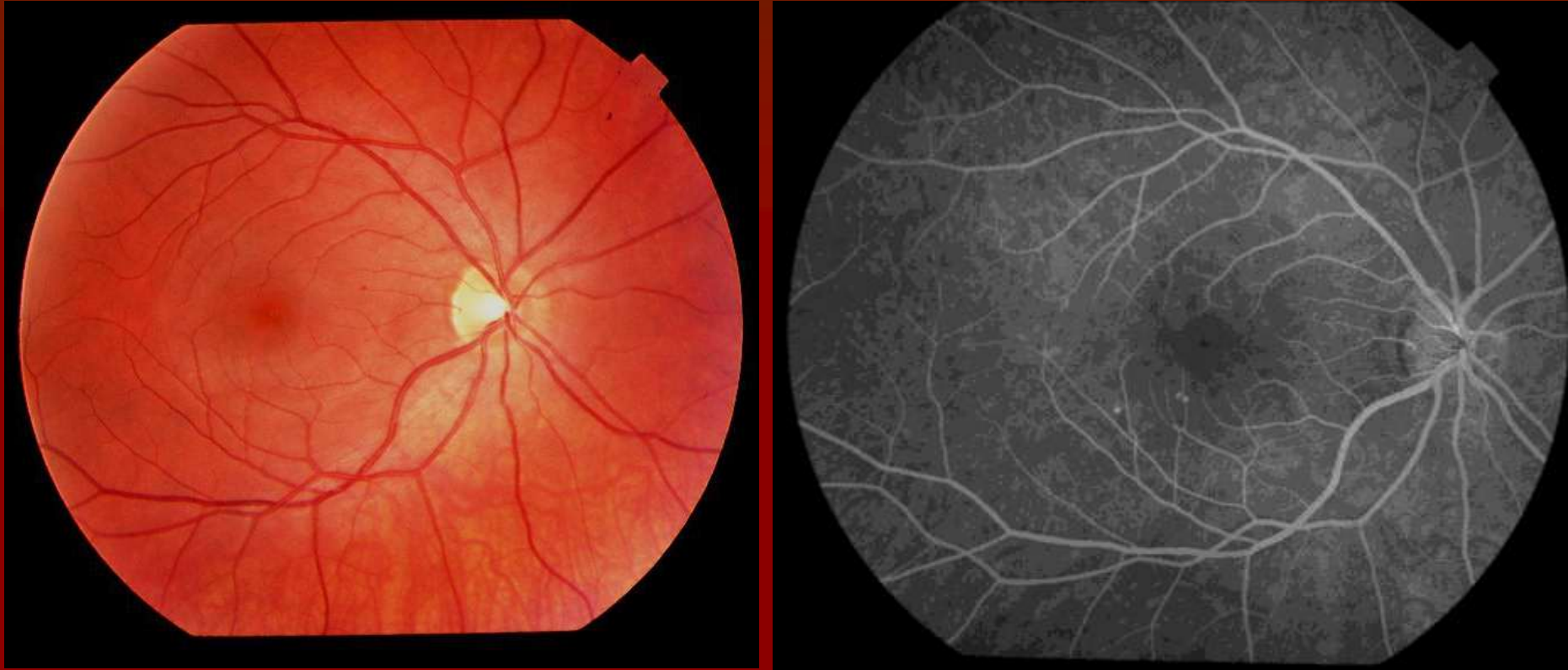
Color Fundus Photo [left] and late-AV phase of fluorescein angiogram [right] of left eye showing increasing hyperfluorescence within the lesions.

FA



Color Fundus Photo [left] and late-AV phase of fluorescein angiogram [right] of left eye showing diffuse hyperfluorescence with blurring of margins within the macula the juxtafoveal lesion.

FA



Color Fundus Photo [left] and early-AV phase of fluorescein angiogram [right] of left eye showing a few scattered hyperfluorescent spots in the inferior macula.

Assessment/Differential Diagnosis

- 22 year old caucasian female with multiple discrete hypopigmented spots throughout the fundus of the left eye (peripheral spots described but not photographed) and juxtafoveal choroidal neovascular membrane associated with subretinal fluid. Fluorescein angiogram shows increasing hyperfluorescence in the juxtafoveal area corresponding to the neovascular membrane and subretinal fluid. No intraocular inflammation was noted during exam.

DDx:

- **Presumed Ocular Histoplasmosis Syndrome**
- Punctate Inner Choroidopathy
- Multifocal Choroiditis & Panuveitis

Plan

- Photodynamic Therapy (PDT)
- Intravitreal Triamcinolone
- Follow up (1 month later):
 - Resolution of leakage on FA

Clinical Course

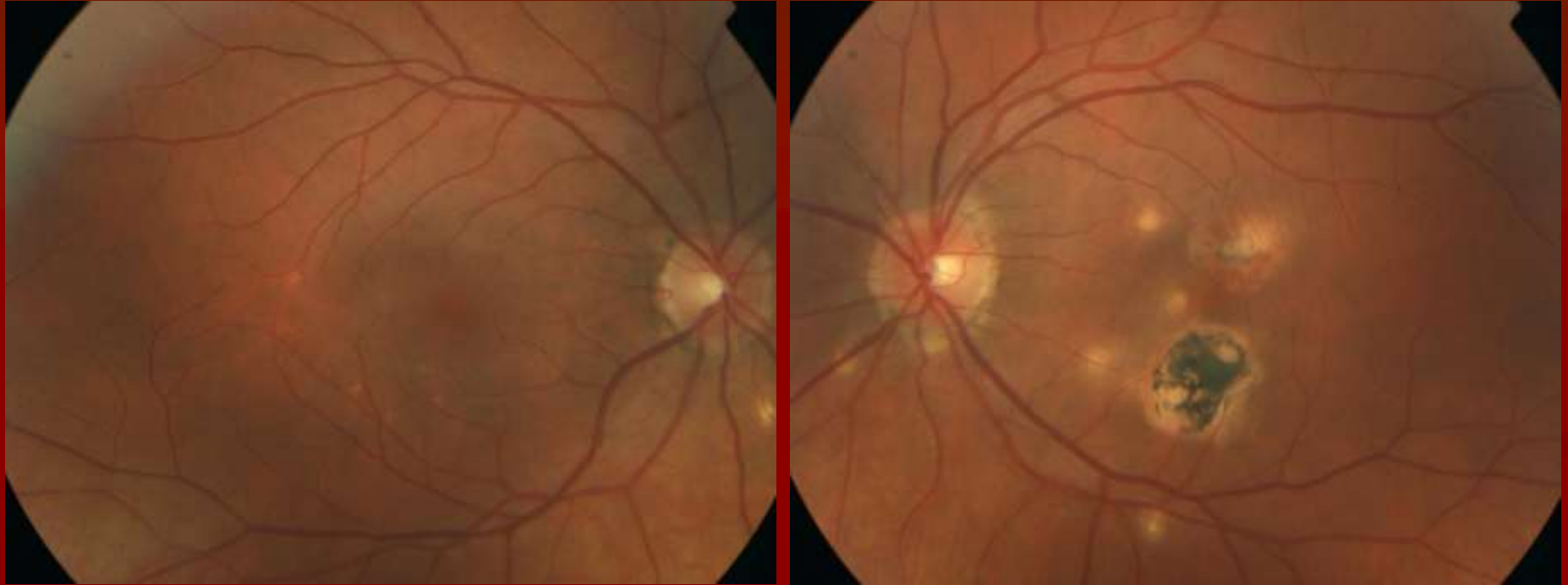
- Over the ensuing 5 years, the patient required periodic PDT for recurrence of CNVM

Most recent visit (July 2010)

	OD	OS
<u>BCVA:</u>	20/20	20/25

Fundus photos

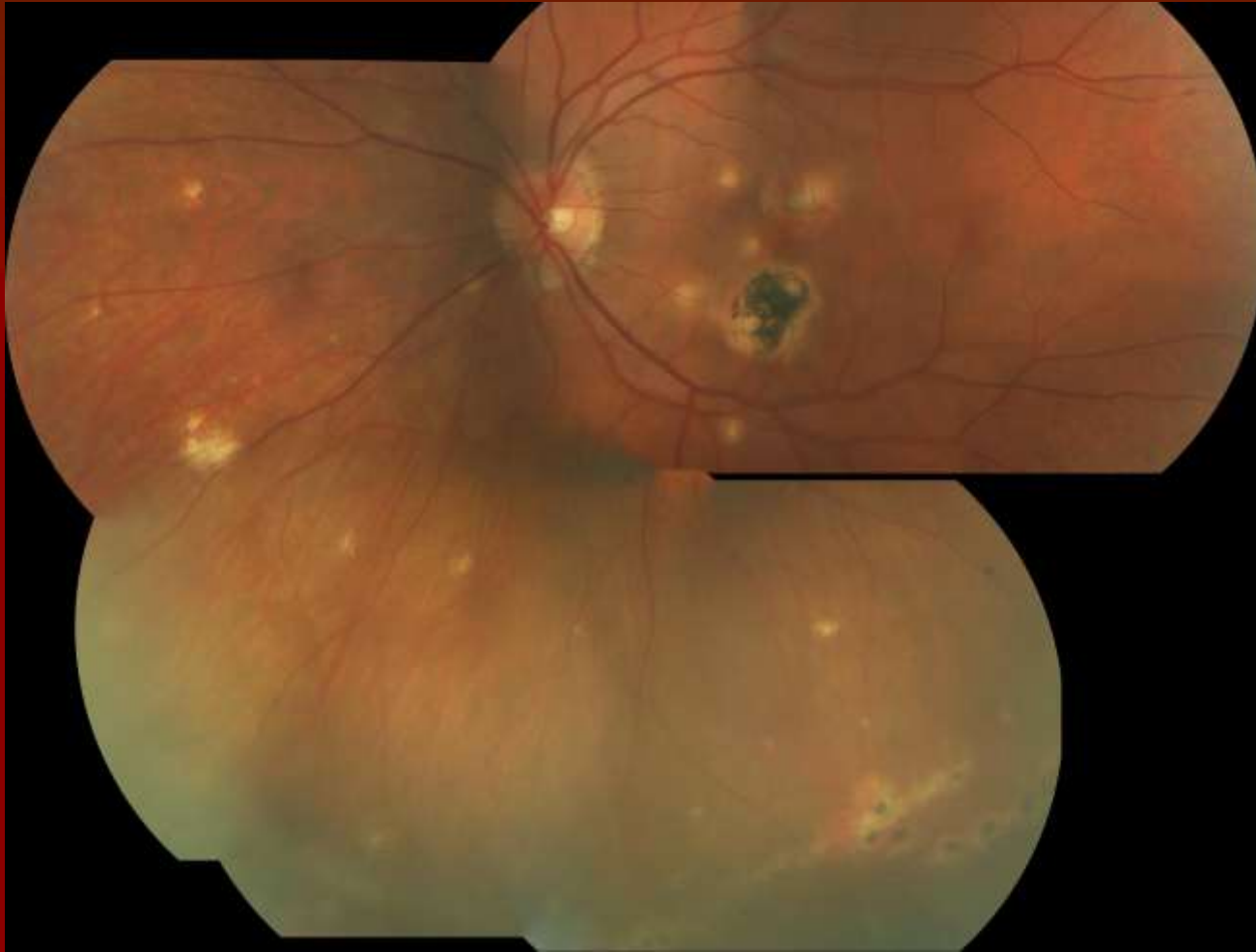(5 years later)



Color fundus photo of right eye [left] with few scattered hypopigmented lesions in the macula and inferior to the optic nerve. Some hyperpigmentation is noted around the nerve.

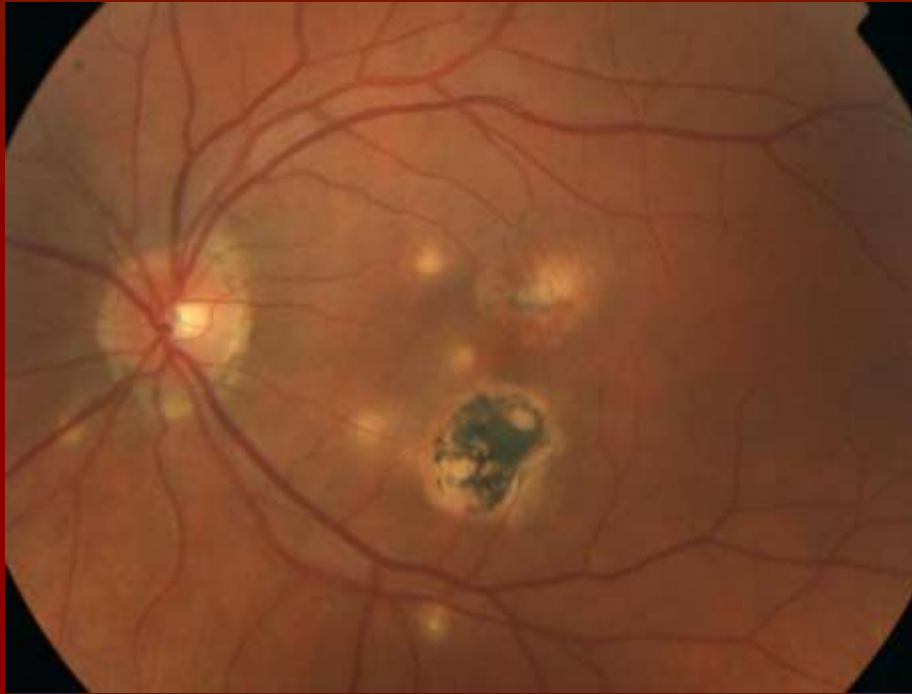
Color fundus photo of left eye [right] with scattered hypopigmented lesions within the macula and near the optic nerve. Areas of peripapillary atrophy and hyperpigmentation are appreciated, and larger atrophic and hyperpigmented scars are also seen.

Mosaic Color Photo



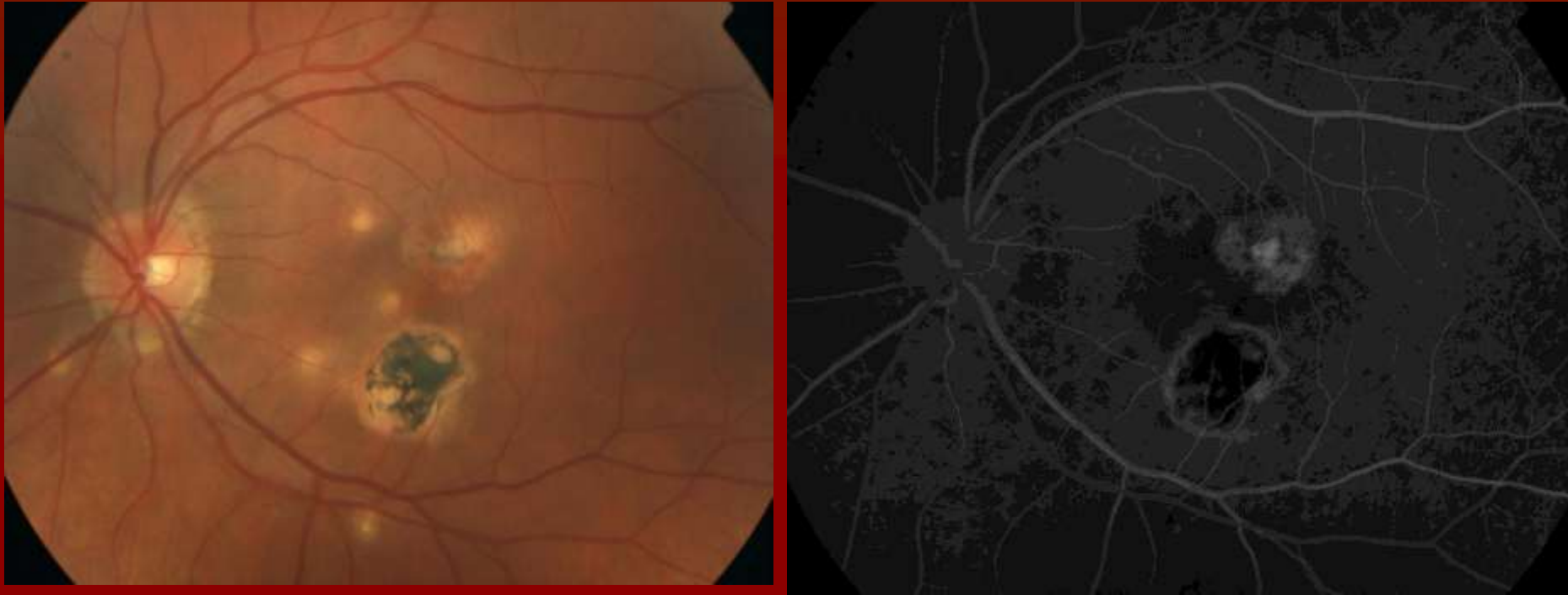
Mosaic color photo of the left fundus showing previously seen macular lesions as well as multiple peripheral lesions.

FA



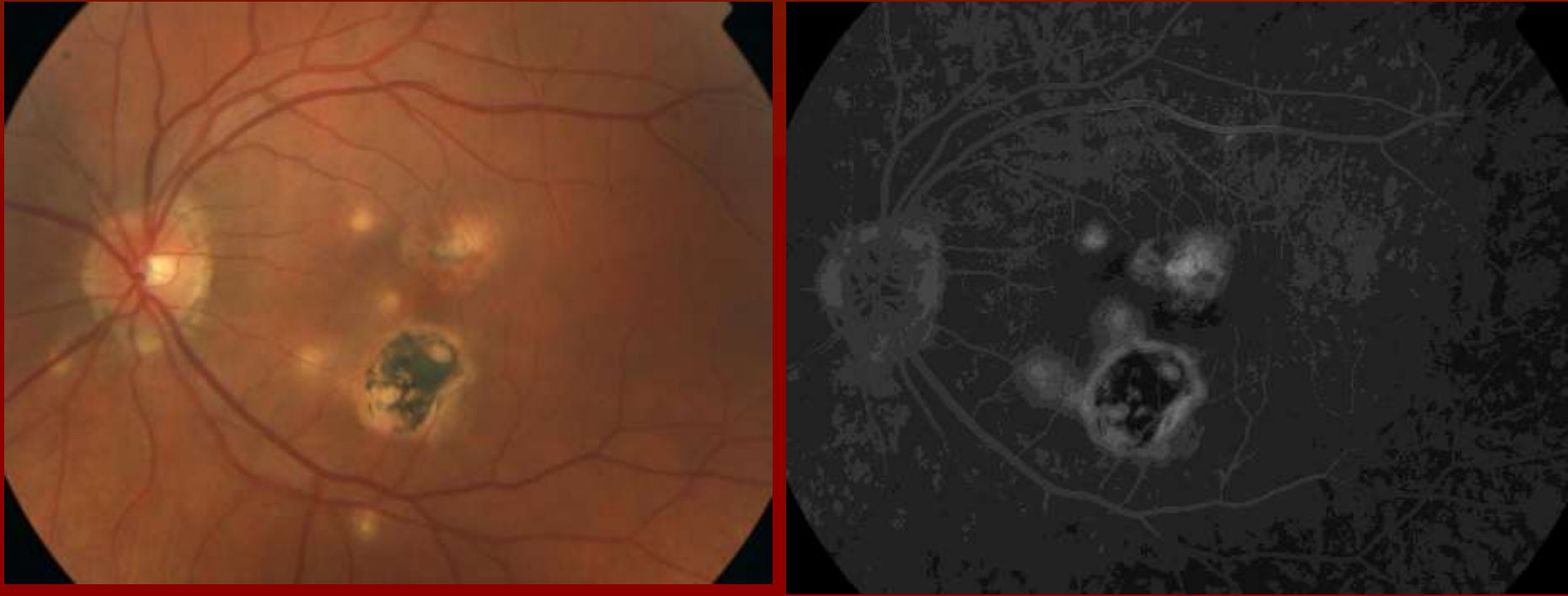
Color Fundus Photo [left] and early-AV phase of fluorescein angiogram [right] of right eye showing hyperfluorescence of hypopigmented areas surrounding macular scars.

FA



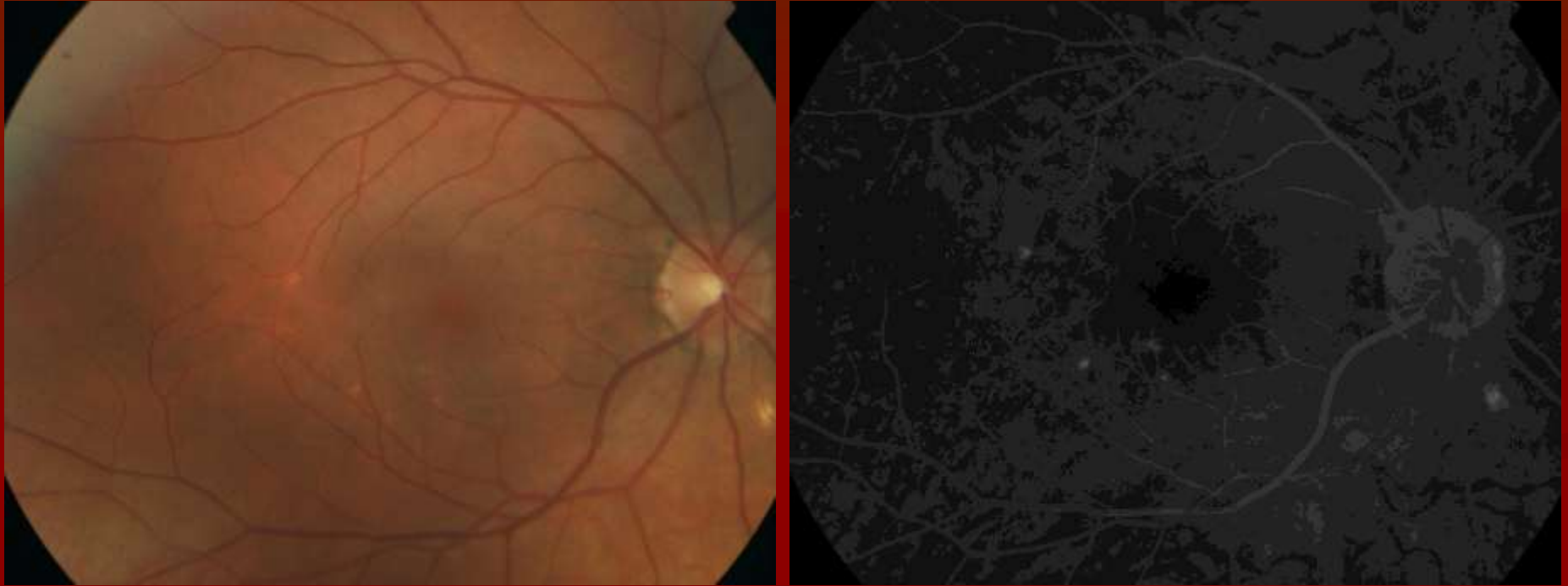
Color Fundus Photo [left] and late-AV phase of fluorescein angiogram [right] of right eye showing fine diffuse hyperfluorescence in the macula near the fovea.

FA



Color Fundus Photo [left] and recirculation phase of fluorescein angiogram [right] of right eye showing hyperfluorescence associated with areas of hypopigmentation.

FA



Color fundus photo [left] and late recirculation phase [right] of the right eye showing hyperfluorescence associated with areas of hypopigmentation.

Which is more likely?

■ POHS

- Believed to be secondary to exposure to *Histoplasma capsulatum*
- Causal relationship has not been definitively proven
- Supported by epidemiologic & histopathologic data

■ PIC

- Inflammatory disorder of the retina and choroid

■ Multifocal Choroiditis

- Inflammatory disorder of the retina and choroid with many similar characteristics as PIC, but some important differences

POHS

■ Presentation:

- Usually asymptomatic until the development of:
 - Choroiditis
 - Choroidal Neovascular Membrane
- Decreased visual acuity, photopsias, scotomas

■ Typical Demographics:

- No sex predilection
- 20-50 years of age
- Endemic to certain areas (river valley climates)

■ Fundoscopic Findings:

- Atrophic chorioretinal scars (“histo spots”) typically in the periphery
- Peripapillary pigment changes
- No vitritis

PIC

■ Presentation:

- Bilateral loss of central visual acuity
- Photopsias, scotomas

■ Typical Demographics:

- Usually females
- Range: 16-40 years with average age at presentation of 26.
- Often Moderately Myopic

■ Fundoscopic Findings:

- Small (100-300um) round yellow-white lesions at the level of the RPE or inner choroid
- Lesions often restricted to Posterior pole & arcades
- Mild optic disc edema may be visible
- Recurrences are rare
- Iritis and Vitritis are not seen

Multifocal Choroiditis

■ Presentation:

- Decreased vision
- Floaters
- Photopsias
- Visual field defects

■ Typical Demographics:

- Usually females
- Age Range: 2nd - 6th decades (ave in 40s)

■ Fundoscopic Findings:

- Multiple yellow choroidal lesions (often larger than PIC at 50-1,000 um)
 - Later evolve into chorioretinal scars
- Lesions often located in the Mid periphery / nasal retina
- May have associated CME
- Recurrences are common
- Vitritis, disruption of the peripapillary RPE, and multifocal choroiditis.

Treatments of CNVM

- Avastin / Lucentis
- Laser Photocoagulation
- Verteporfin PDT
- Systemic / Injected Corticosteroids
- Submacular Surgery

References

- Oliver A, Ciulla TA, Comer GM. New and classic insights into presumed ocular histoplasmosis syndrome and its treatment. *Curr Opin Ophthalmol*. Jun 2005;16(3):160-5
- Goldstein DA, Ulanski L. Multifocal choroiditis vs. PIC: Variations on a Theme?. *Review of Ophthalmology*. June 2004; 82-86
- Taira K, Nakazawa M, Takano Y, Ota T Acute zonal occult outer retinopathy in the fellow eye 5 years after presentation of punctate inner choroidopathy. *Graefes Archive for Clinical & Experimental Ophthalmology*. 244(7):880-2, 2006 Jul.
- Watzke RC, Packer AJ, Folk JC, Benson WE, Burgess D, Ober RR. Punctate inner choroidopathy. *Am J Ophthalmol*. 1984;98:572-584
- A. S. Berger, M. Conway, L. V. Del Priore, R. S. Walker, J. S. Pollack and H. J. Kaplan. Submacular surgery for subfoveal choroidal neovascular membranes in patients with presumed ocular histoplasmosis; *Arch Ophthalmol* 1997; 115(8):991-6
- Dreyer RF and JDM Gass. Multifocal choroiditis and panuveitis: a syndrome that mimics ocular histoplasmosis. *Archives of Ophthalmology* 1984;102:1776-1784
- Watzke RC, Packer AJ, Folk JC, Benson WE, Burgess D, and RR Ober. Punctate inner choroidopathy. *Am J Ophthalmology* 1984;98:572-584.

Thank You!